



The El Paso Physician

Official publication of the El Paso County

Medical Society and District 1 of the Texas Medical Association

NEWLY DEDICATED!

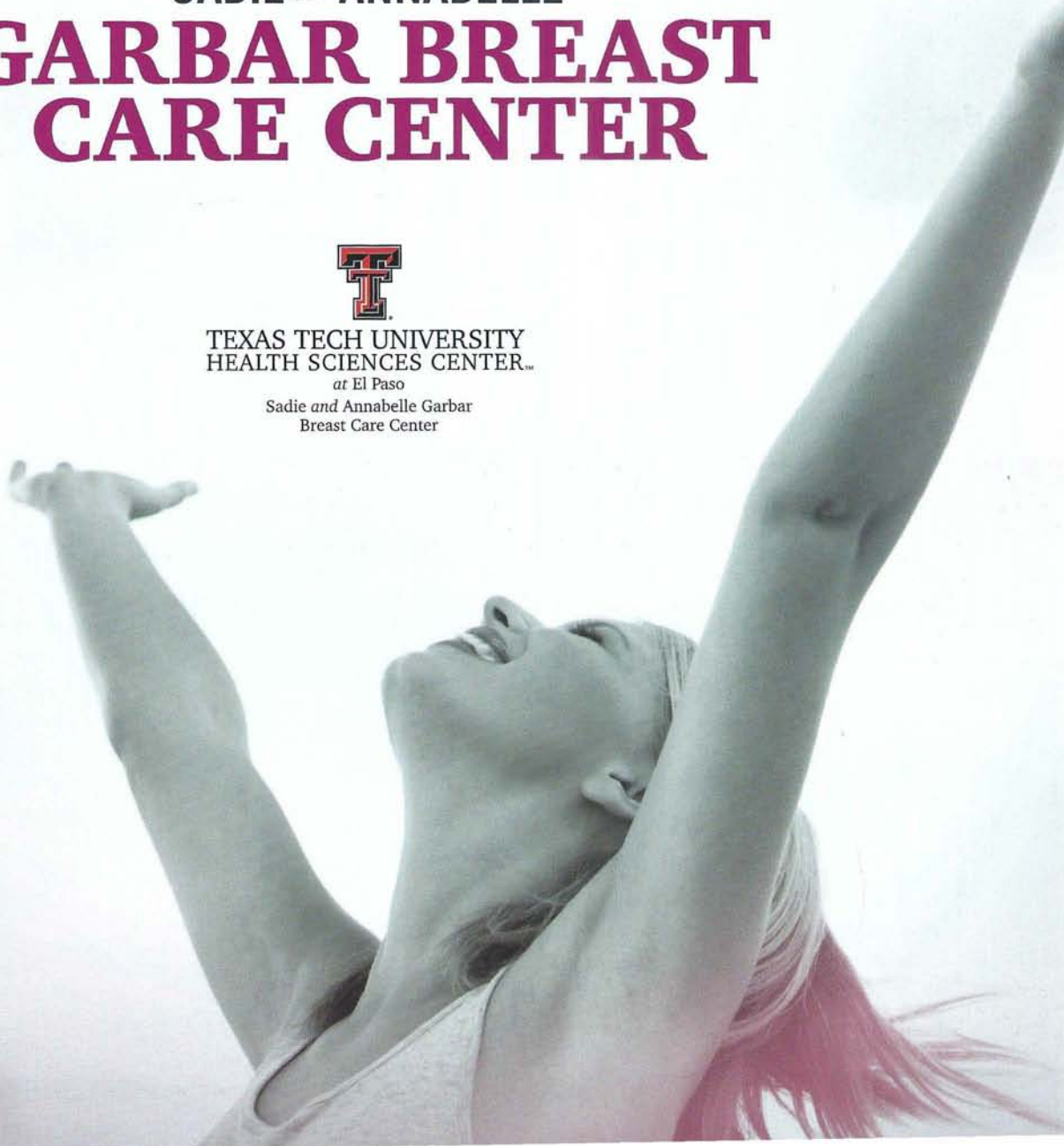SADIE AND ANNABELLE GARBAR BREAST CARE CENTER



TEXAS TECH UNIVERSITY
HEALTH SCIENCES CENTER..

at El Paso

Sadie and Annabelle Garbar
Breast Care Center



CR

CASE REPORT

E.P.C.M.S.

Timing, Techniques, and Options for Breast Reconstruction After Breast Cancer: A Brief Review of the Current Literature

Alonzo Molinar, MSIV

Vanessa E. Molinar, MSIII

Humberto Palladino, M.D.

Francisco J. Agullo, M.D., FACS (Corresponding Author)

ABSTRACT

Breast cancer is an unfortunately common disease affecting millions of women of various age groups. Reconstruction following mastectomy allows women to pacify the stress and emotional anxiety experienced after the devastating diagnosis and mastectomy to follow. Selecting the appropriate timing for breast reconstruction after a mastectomy and best method of reconstruction are important to achieve the best outcome and to minimize postoperative complications. Surgeons must decide on immediate versus delayed reconstruction based on breast cancer stage, status of axillary sentinel lymph nodes, smoking status, body habitus, preexisting scars, prior radiation therapy, and previous or post-chemotherapy. Plastic surgeons must also spend time properly informing patients about the safety and limitations of the various techniques such as autologous reconstruction, expander, and implant reconstruction. This article summarizes the various approaches to breast reconstruction and will discuss risks and benefits of each.

INTRODUCTION

In 2012, it is estimated that there were more than 2.9 million women living in the US with a history of breast cancer, and an additional 226,870 women will be diagnosed.¹ About 20% of breast cancers occur among women younger than age 50 and about 40% occur in those older than 65 years old.¹ Mastectomy plays a major role in the treatment algorithm of breast cancer, and as a result, women are also faced with the decision to undergo reconstruction for a better aesthetic result and for improved self-confidence and mental health. The other common group of patients undergoing breast cancer surgery are, subject to what is commonly known as lumpectomies or breast conservative surgery (BCS). This technique allows for a less invasive approach while occasionally leaving significant deformities and assuring the need of postmastectomy radiation therapy (PMRT). Surprisingly, only 30% of women undergoing breast cancer treatment in the United States are aware of or have been informed of their options for breast reconstruction.

The timing of breast reconstruction after mastectomy depends on clinicopathologic factors as well as technique utilized for reconstruction. Immediate breast reconstruction is usually, but not always, reserved for patients with clinical Stage I breast cancer and some patients with clinical Stage II breast cancer who do not have an increased risk requiring postmastectomy radiation therapy (PMRT).² Comparatively, delayed breast reconstruction is usually reserved for patients who will require

postmastectomy radiation therapy. For these patients, surgeons must utilize autologous reconstruction techniques due to acute problems associated with wound healing and capsular contracture, which can cause painful complications.²

Aside from deciding on the timing of reconstruction, an ultimate decision on reconstruction technique must be evaluated by both the patient and surgeon. Current options include expander/implant reconstruction, autologous reconstruction including the transverse rectus abdominis myocutaneous, (TRAM) flap procedure and latissimus dorsi myocutaneous flap, free flaps, and autologous fat grafting.

IMMEDIATE BREAST RECONSTRUCTION

Immediate breast reconstruction is an essential part of breast cancer treatment with positive aesthetic and psychological results. As discussed previously, this option is reserved for patients with clinical stage I and II breast cancer who will not undergo postmastectomy radiation therapy. Advantages to immediate breast reconstruction include better aesthetic outcome because of preservation of the breast skin envelope, and there is a positive psychologic outcome giving patients a greater sense of self-esteem and freedom to wear the clothes they desire.^{2,3} There is not a general consensus among studies that reconstruction should be delayed in patients who, are known to require postmastectomy radiation therapy.

POSTMASTECTOMY RADIATION THERAPY

Unfortunately, the need for postmastectomy radiation therapy is not always known at the time of mastectomy. It is known that for patients with implant reconstruction, radiation can promote capsular fibrosis, which distorts the appearance of the breast and chronic chest wall pain and tightness, and delayed wound healing.³

Patients receiving postmastectomy radiation therapy have stage 2 and 3 breast cancer with advanced disease. They often have a poor prognosis and they may not want to undergo or be candidates for autologous reconstruction. Immediate implant reconstruction (one- or two-stage) provides the simplest surgical solution for this group of patients who will need neoadjuvant/ adjuvant chemotherapy and postmastectomy radiation therapy. Breast reconstruction in this scenario can be incredibly worthwhile from the patient's perspective.

The fact that reconstruction is fraught with higher but often-ac-

Continued on page 26

**Timing, Techniques, and Options for Breast Reconstruction After Breast Cancer:
A Brief Review of the Current Literature
(Continued)**

ceptable complication rates and lesser outcomes should not mean that this approach is an absolute contraindication. A majority of these patients are extremely grateful and remain satisfied with their results despite potentially marginal aesthetic outcomes.^{4,5}

To address the dilemma of postmastectomy radiation therapy in a patient who desires immediate reconstruction, delayed-immediate reconstruction is an option. A tissue expander is placed at the time of mastectomy, and if postmastectomy radiation therapy is required, the tissue expander can be expanded up to the time of irradiation.³ It can be re-inflated after completion of therapy and a second stage of autologous reconstruction is planned. Some advocate rapid expansion and implant exchange prior to radiation, but never compromising the cancer treatment itself.⁵

DELAYED BREAST RECONSTRUCTION

Delayed breast reconstruction is reserved for most patients who will require postmastectomy radiation therapy (PMRT). Currently, many centers in the U.S. recommend postmastectomy radiation therapy for patients with breast cancer who have 1 to 3 positive lymph nodes.² Challenges in delayed reconstruction include resecting irradiated scar between the mastectomy scar and inframammary fold because it is inflexible and does not allow for reconstruction of a curved and ptotic-breast.² The preferred technique in this circumstance is autologous reconstruction with tissue flaps because of increased complications in breast implants associated with postmastectomy radiation therapy.

EXPANDER/IMPLANT RECONSTRUCTION

The tissue-expansion technique involves the initial submuscular placement of a tissue expander, which is an adjustable breast implant that contains a saline-filling port which can be accessed easily by placing a needle through the skin.² The implant is supported inferiorly by a tissue matrix mesh. The expansion process ranges from 1 to 3 months after mastectomy, in which multiple postoperative visits are made for expansion of the breast envelope. The final exchange for a silicone gel implant is then completed. Disadvantages to the tissue-expansion method include the requirement of a 2-stage approach (second surgery to exchange expander for implant), difficulty obtaining symmetry with con-

tralateral breast, and increased risk of infection because tissue expander is a foreign body.² An advantage to the tissue-expansion technique is that surgical and recovery time are most rapid compared to other procedures.² Some patients undergoing nipple sparing or skin sparing mastectomies may be candidates for one stage reconstruction with immediate placement of a silicone implant.

LATISSIMUS DORSI MYOCUTANEOUS FLAP

In this technique, an implant or tissue expander can also be utilized. The combined latissimus dorsi flap with breast implant is a good option in obese patients in whom TRAM or free flap procedures are not safe to perform and in thin patients who are not candidates for TRAM flap because of inadequate tissue for reconstruction or closure of donor site.² The skin island that is included with this technique can replace any resected skin including nipple-areolar complex to retain the initial shape of the breast skin envelope. The volume of the breast is often achieved with an implant or expander. Thus, it creates a more natural and ptotic-appearing breast.² Another advantage opposed to tissue expansion, a second surgical procedure is not always required. Unfortunately, disadvantages include a longer recovery period (4 weeks), atrophy of the latissimus muscle over time making the underlying implant more prominent and surface thickness irregularities.²

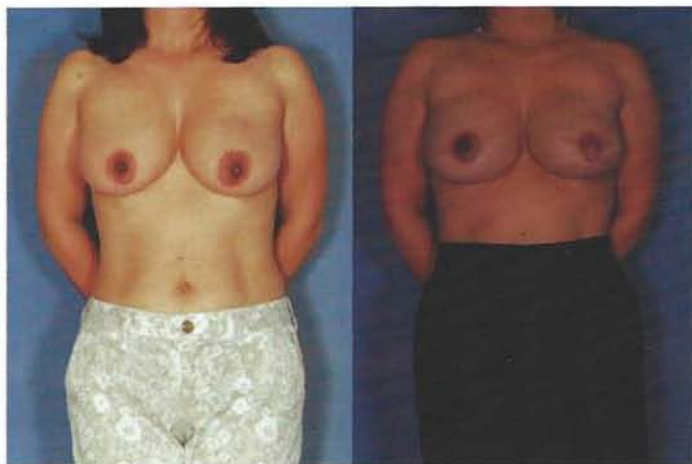

Figure 1. Patient with left breast cancer undergoing immediate reconstruction after skin and nipple sparing mastectomies with implants.

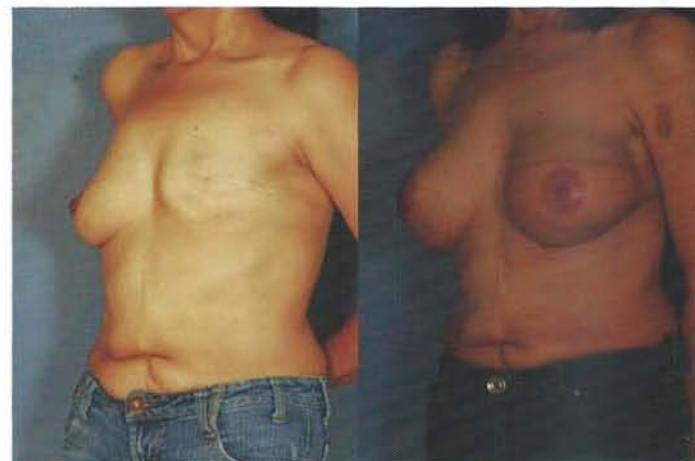

Figure 2. 42 year old female with history of left mastectomy and radiation with left Latissimus Dorsi flap and implant reconstruction.

TRAM FLAP

Breast reconstruction with a TRAM flap is associated with long and arduous recovery, requiring some patients to miss work for 2-6 weeks and a need for good support system.² A TRAM flap resembles normal breast tissue and can result in a natural appearing reconstructed breast. In addition, this method has the added benefit of concomitant abdominoplasty, which many women find appealing and allows them to focus on a positive aspect when they are undergoing negative changes affecting their body image. Disadvantages to this technique is the increased risk of complications after reconstruction in obese patients (BMI of <30 kg/m² is preferred) and in those who smoke.² Complications are related to decreased blood supply to TRAM flap causing fat necrosis and wound healing problems at the lower abdominal donor site, in-

Continued on page 27

**Timing, Techniques, and Options for Breast Reconstruction After Breast Cancer:
A Brief Review of the Current Literature
(Continued)**

cluding abdominal laxity and risk for abdominal hernias.² The same abdominal tissue can also be transferred as a free flap using microvascular anastomosis and leaving some or all of the rectus muscle intact. This surgery is termed free TRAM, muscle sparing free TRAM, or deep inferior epigastric perforator flap (DIEP). In theory, these procedures may decrease the degree of abdominal complications in exchange for considerably longer surgical times.

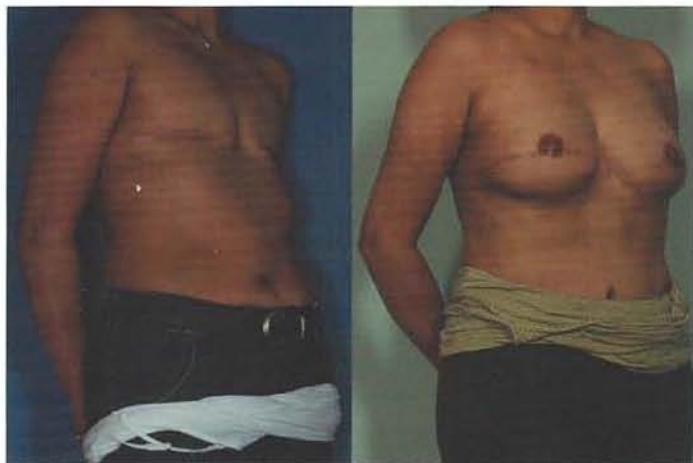


Figure 3. 45 year old female with delayed bilateral TRAM flap reconstruction.

FAT INJECTIONS

Fat injection procedures have become ideal to reconstruct partial mastectomy defects with or without radiation and to mold the reconstructed breast for better symmetry. A clear advantage is decreased recovery time and complications. On the other hand, more than one session may be necessary to achieve optimal goals.

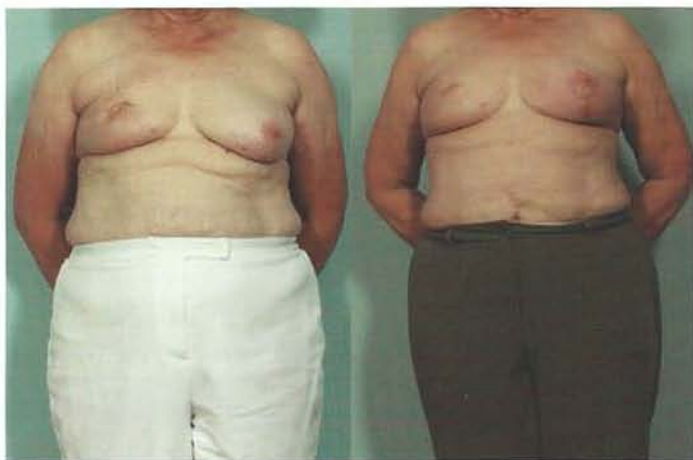

Figure 4. 65 year old female with left breast cancer after lumpectomy and radiation, which underwent right breast fat injections and contralateral breast lift.

DISADVANTAGES OF FAT INJECTIONS

There are several factors to consider in fat injections, the fat injected into the breast area may be reabsorbed by the body over

time and the breast may lose some volume. Another disadvantage is that also some of the fat injected into the breast area may die, which is called “necrosis;” symptoms of necrosis may include pain and bleeding, the skin turning dark blue or black, numbness, fever, and sores that ooze a bad-smelling discharge or pus in some cases. The duration of the fat injections changes patient to patient and is unlikely to know how long it will last.

CONCLUSION

Breast reconstruction is an integral component in the treatment of breast cancer after mastectomy. While there are many options available to the surgeon, every patient is unique and the options available to them are based on their need for post-mastectomy radiation, breast cancer stage, body habitus, and surgeon familiarity with various procedures. The ultimate goals of reconstruction are to provide the best aesthetic outcome, minimal complications, and patient satisfaction.

REFERENCES

1. *Cancer treatment & survivorship facts & figures 2012-2013.* American Cancer Society.
2. Kronowitz, S.J., Kuerer, H.M., *Advances and Surgical Decision-Making for Breast Reconstruction.* *Cancer.* 2006 Sep 1;107(5):893-907.
3. Veronesi, P., De Lorenzie, F., Ballardini, B., et al. *Immediate breast reconstruction after mastectomy.* *Breast.* 2011 Oct;20 Suppl 3:S104-7. doi: 10.1016/S0960-9776(11)70305-8.
4. McCarthy CM, Klassen AF, Cano SJ, et al. *Patient satisfaction with postmastectomy breast reconstruction: A comparison of saline and silicone implants.* *Cancer.* 2010;116:5584-5591.
5. Ho A, Cordeiro P, Disa J, et al. *Long-term outcomes in breast cancer patients undergoing immediate 2-stage expander/implant reconstruction and postmastectomy radiation.* *Cancer.* 2012 May 1;118(9):2552-9.
6. Serlletie, J., Fosnot, J., Nelson, J. et al. *Breast Reconstruction after Breast Cancer.* *Plast Reconstr Surg.* 2011 Jun;127(6):124e-35e.

Alonzo Molinar, MSIV, Central America Health Science University.

Vanessa E. Molinar, MSIII, Texas Tech University Health Sciences Center - Paul L. Foster School of Medicine.

Humberto Palladino, M.D, Assistant Professor of Plastic Surgery, Texas Tech University Health Sciences Center - Paul L. Foster School of Medicine.

Francisco J. Agullo, M.D, FACS, Associate Professor of Plastic Surgery, Texas Tech University Health Sciences Center - Paul L. Foster School of Medicine. (Corresponding Author)